

The Association between Lichen Planus and Hepatitis C Virus

Hasnaa A. Abo-Elwafa^{*1}, Esam-Eldeen A. Nada², Reham, E. El-Sharkawy² and Nesreen A. Abdel-Rahman²

Clinical Pathology Department¹, Dermatology and Venereology Department², Faculty of Medicine, Sohag University, Egypt

*aboelwafahasnaa@yahoo.com

Abstract: Background: Hepatitis C virus, has been associated with a wide variety of extrahepatic manifestations (EHM) in the natural history of the disease. Lichen planus (LP) has also been reported in association with the hepatitis C virus. Objective is to determine the frequency of HCV in patients with LP in Sohag University Hospital. Patients and methods: The study was carried out in Sohag University Hospital in Clinical Pathology Department and Dermatology Venereology Department from October 2009 to April 2010, on 70 patients with LP (34 males, 36 females) their age ranged from 25 to 80 years old, and 20 patients (11 males, 9 females) their age ranged from 22 to 70 years old as a control group with other dermatological manifestations. Patients were recruited from the out patient clinic of dermatology department, full history, clinical examination, biopsy in some cases to confirm the diagnosis of LP and laboratory investigations for anti-HCV detection, liver function tests were done. Results: There was insignificant difference between LP group and the control group regarding the age or the sex ($p = 0.176$). There was a highly significant increase in HCV infection between LP group ($p = 0.000$), a significant increase in HCV infection among the old age patients ($p = 0.008$) was found, HCV infection and duration of LP showed a significant correlation ($p = 0.022$). There was an increase in aspartate aminotransferase (AST) in actenic LP patients and mucous LP patients compared with those of classic type ($p = 0.028$). Conclusion: A possible relationship between LP and HCV, thus, it seems that the HCV antibody test is necessarily required for LP patients.

[Hasnaa A. Abo-Elwafa, Esam-Eldeen A. Nada, Reham, E. El-Sharkawy and Nesreen A. Abdel-Rahman. **The Association between Lichen Planus and Hepatitis C Virus.** Journal of American Science 2011; 7(2):277-282]. (ISSN: 1545-1003). <http://www.americanscience.org>.

Key words: Lichen Planus- HCV Infection

1. Introduction:

Infections with hepatitis viruses, have been associated with a wide variety of extrahepatic manifestations (EHM)¹. Several (EHM) had been reported in the natural history of HCV infection². This included mixed cryoglobulinemia, autoimmune thyroiditis, non-Hodgkin's lymphoma, lymphoproliferative disorders and some cutaneous manifestations, such as porphyria cutanea tarda, leukocytoclastic vasculitis, LP (lichen planus), sicca syndrome and others³.

It was found that Egypt reports the highest prevalence of HCV worldwide, ranging from 6 % to more than 40 % with an average of 13.8%. Injection therapy for schistosomiasis, and needles were frequently reused, despite termination of this program and the implementation of measures designed to reduce hospital-related infection, transmission continues, including a cut puncture and cutting of the skin with unsterilized knives were likely transmission modes^{4,5}.

Elevations of aspartate amino transferase (AST) and alanine amino transferase (ALT) level indicated the presence of liver injury. Patients with chronically elevated aminotransferase values should

undergo a workup to exclude the possibility of chronic liver disease¹. Due to the lack of symptoms, the vast majority of chronically infected individuals remain undiagnosed and unaware of the infection for several years⁶. Fibroscan is not currently licensed for use in the United States⁷. Future generations of serologic fibrosis markers may have greater accuracy and may obviate the need for liver biopsy⁸.

Lichen planus (Greek *leichen*, "tree moss"; Latin *planus*, "flat") is a unique, common inflammatory disorder that affects the skin, mucous membranes, nails, and hair. The appearance of lichen planus (LP) and lichen planus-like or lichenoid dermatoses has been likened to the scurfy, finely furrowed, dry excrescences of the symbiotic vegetation known as lichen⁹. Cell-mediated immunity plays the major role in triggering the clinical expression of the disease. Both CD4+ and CD8+ T cells are found in the skin lesion of LP¹⁰.

LP had also been reported in association with the hepatitis C virus (HCV)¹⁰. While other studies had rejected such an association^{11,12}.

LP may be the first presentation of HCV infection^{10,13}. The oral form of LP seems more common¹⁴. The differential diagnosis of LP actinicus

includes polymorphous light eruption, granuloma annulare, sarcoidosis, melasma and erythema dyschromicum perstans¹⁵. The LP-HCV association cannot be explained on the basis of high HCV seroprevalence in the general population only. Possible genetic differences among the populations studied (HLA-DR6 allele in Italy)^{16,17}.

The aim of the present study is to determine the frequency of HCV in patients with LP in Sohag University Hospital.

2. Patients and methods:

This study was carried out in Sohag University Hospital in Clinical Pathology Department and Dermatology Venereology Department from October 2009 to April 2010, on 70 patients with LP (34 males, 36 females) their age ranged from 25 to 80 years old as the study group, and 20 patients (11 males, 9 females) their age ranged from 22 to 70 years old as a control group with other dermatological manifestations. Patients were recruited from the out patient clinic of dermatology department. A written informed consent was taken from them. The study was approved by the Ethical Committee of Sohag Faculty of Medicine.

Exclusion criteria included cases with lichenoid drug eruption.

Each subject was evaluated for full history, clinical examination to detect the type, extent and severity of the disease. Biopsy was taken from some cases to confirm the diagnosis of LP and laboratory investigations included anti-HCV detection, liver function tests.

Details of blood sampling and laboratory techniques:

Five ml of venous blood was drawn from every patient, added to the appropriate vacutainer for liver function tests; anti-HCV detection.

Liver Function Tests:

Liver function tests were performed on fully automated chemical autoanalyzer Synchron CX-9 (Beckman) system by the use of kits supplied by Beckman Coulter/France, serum aspartate aminotransferase (AST) Cat No. 446265, serum alanine aminotransferase (ALT) Cat No. 442620, serum total bilirubin (TBIL) Cat No. 442745 and serum albumin Cat No. 442765.

Anti-HCV Detection:

Anti-HCV detection was performed by using ARCHITECT Abbott System, MEIA (microparticle enzyme immunoassay) technology; which is a variation of the ELISA principle HCV version 3 (recombinant HCr43, c200, c-100-3, NS5).

Statistical methods:

The data was processed and analyzed using the Statistical Package of Social Sciences (SPSS) version 9. Frequency, percentage, mean and standard deviation were calculated. Chi square test was used to compare the percentage while t-test and ANOVA test were used to compare means, p-value significant at level < 0.05.

3. Results:

The demographic data of the studied groups were illustrated in table 1. There was insignificant difference between LP group and the control group regarding age or sex (p = 0.176).

HCV was found to affect 27 patients (38.6%) of LP group, and only 2 patients (10%) of the control group. There is highly significant increase in HCV infection among LP group compared to the control group (p = 0.000) (table 2).

The relation between age and anti-HCV antibodies in LP group showed that HCV was found to affect 18 patients (50%) out of 36 patients more than 50 years old, and 9 patients (33.3%) out of 22 patients aged 30-50 years old. Patients aged less than 30 years old were all not affected by HCV, they were 12 patients (17.2%). Generally there was a significant increase in HCV infection among older patients (p = 0.008) (table 3).

Relation between anti-HCV antibodies and the duration of LP showed the negative HCV antibody was found in patients less than 1 year duration and the positive HCV antibody was found among those with duration more than 10 years (p = 0.022), but the relation was not significant in those LP patients with duration 1-10 years (table 4 fig 1).

Liver function tests examination in LP subtypes represented an increase in the total bilirubin concentration in actenic LP patients (1.53 mg/dl) compared to those with mucous LP (1.37 mg/dl) and classic type (1.08 mg/dl) however this increase was insignificant (p = 0.095). There was an increase in AST level in actenic LP patients (40.42 IU/L) and mucous LP patients (40.10 IU/L) compared to those of classic type (27.04 IU/L), this increase was significant (p = 0.028).

Also there was an increase in ALT level in actenic LP patients (45.00 IU/L) and mucous LP patients (44.33 IU/L) compared with classic type (31.87 IU/L), this increase was significant (p = 0.041). The serum albumin concentration was higher in both classic and actenic LP patients than in mucous type (3.58 g/dl, 3.568 g/dl, 3.44 g/dl respectively), but this increase was insignificant (p = 0.906) (table 5).

Relation between anti-HCV antibodies and pruritis, 20 patients (74.1%) out of 27 patients with LP and

HCV positive were suffering from severe pruritis, but generally the relation between pruritis and HCV infection was insignificant ($p = 0.399$), (table 6).

Table (1): Demographic data in LP group and the control group

Group / Gender		Mean age (year)	S.D	p - value
Control group (n= 20)	Male (n =11)	42.09	17.28	0.176 NS
	Female (n = 9)	42.11	13.76	
LP group (n = 70)	Male (n = 34)	46.09	18.14	
	Female (n = 36)	49.47	15.70	

NS: non significant $p > 0.05$

Table (2) The LP and control groups regarding the anti HCV antibodies:

Group	Control group (n= 20)		LP group (n= 70)		p -Value	
	No.	%	No.	%	Value	Comment
Anti-HCV						
Negative	18	90%	43	61.4%	0.000002	H.S
Positive	2	10%	27	38.6%	0.000002	H.S

H.S: Highly Significant $p < 0.001$

Table (3):The relation between age and anti-HCV in LP patients

Anti HCV	Negative HVC (n= 43)		Positive HCV (n= 27)		Total (n= 70)	
	No.	%	No.	%	No.	%
Age group						
< 30 years	12	27.9%	0	0.0%	12	17.14%
30 – 50 years	13	30.2%	9	33.3%	22	31.43%
> 50 years	18	41.9%	18	66.7%	36	51.43%
Total (n= 70)	43	61.4%	27	38.6%	70	100%
p - value	p = 0.008 significant					

Table (4): Relation between anti-HCV antibodies and duration of LP

Anti HCV	Negative (n= 43)		Positive (n= 27)		Total (n= 70)		p - value	
	No.	%	No.	%	No.	%	Value	Comment
Duration								
< 1 year	29	67.4%	13	48.1%	42	60.0%	0.006	HS
1 -10 years	13	30.2%	8	29.6%	21	30.0%	1.00	NS
> 10 years	1	2.3%	6	22.2%	7	10%	0.0001	HS
p – value	0.022 S							

S: Significant $p < 0.05$ HS: Highly Significant $p < 0.001$ NS: Non Significant $p > 0.05$

Table (5): Liver function tests in LP subtypes

LP Subtypes		Mucus (n = 21)		Atenic (n = 19)		Classic (n = 41)		p – value	
		Mean	S.D	Mean	S.D	Mean	S.D	Value	comment
Bilirubin mg/dl	Total	1.3762	1.331	1.532	1.425	1.083	0.6356	0.095	NS
	Direct	0.4429	0.829	0.200	0.0882	0.298	0.6136	0.417	NS
AST IU/L		40.105	29.85	40.421	31.117	27.049	15.129	0.028	S
ALT IU/L		44.338	30.63	45.00	33.543	31.878	15.302	0.041	S
Albumin g/dl		3.443	0.572	3.568	0.656	3.588	0.5528	0.906	NS

NS: Non Significant $p > 0.05$ S: Significant $p < 0.05$

Table (6): Relation between anti-HCV antibodies and pruritis

Anti HCV		Negative (n= 43)		Positive (n= 27)		Total (n = 70)		p- Value	
		No.	%	No.	%	No.	%	Values	comment
Pruritis									
No.		8	18.6%	3	11.1%	11	15.7%	0.113	NS
Mild		10	23.3%	4	14.8%	14	20.0%	0.149	NS
Severe		25	58.1%	20	74.1%	45	64.3 %	0.0006	S
p- value		0.399 NS							

S : Significant $p < 0.05$ NS : Non Significant $p > 0.05$

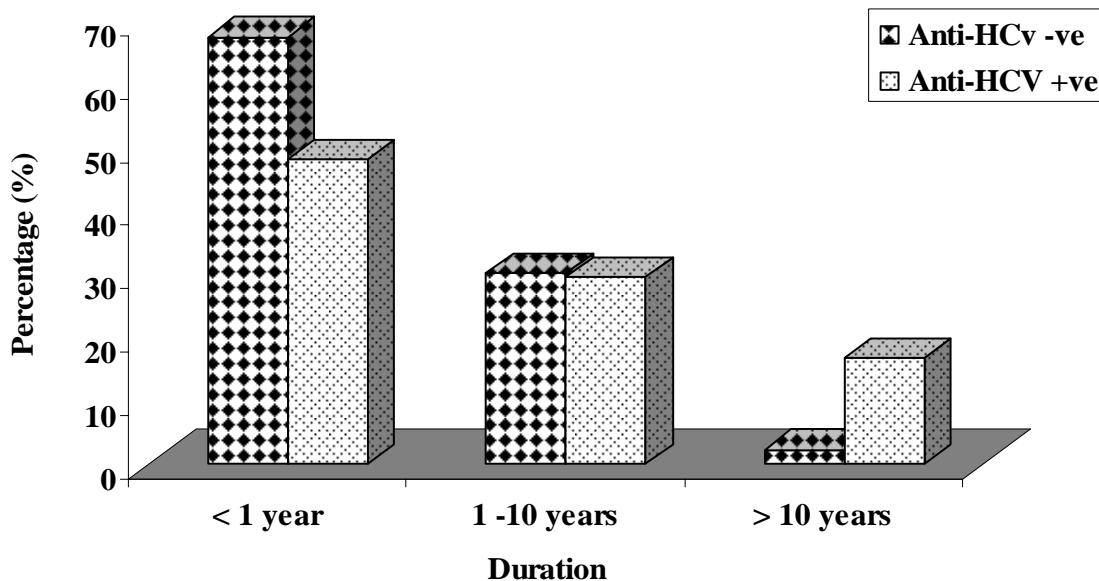


Figure (1): Relation between anti-HCV antibodies and duration of LP

4. Discussion:

LP is a chronic papulosquamous inflammatory disease of unknown etiology that affects the skin, mucous membranes, nails and hair with the prevalence up to 2 % . Theories of infectious

(e.g HCV, herpes simplex viruses), autoimmune, metabolic or genetic causes have been proposed¹⁸ .

HCV is an enveloped, single-stranded positive-sense RNA virus that was isolated in 1989 from a chimpanzee chronically infected by

contamination with a human factor VIII concentrate¹⁹. HCV is the main causative agent of parenterally transmitted non-A, non-B viral hepatitis with 3% of the world population being infected^{20,21}.

Chronic hepatitis C infection is characterized by wide spectrum of liver damage ranging from mild chronic hepatitis to cirrhosis and even hepatocellular carcinoma, as well as the leading indication for liver transplant²².

Extra hepatic manifestation (EHM) of HCV infection is predominantly of possible autoimmune origin and many of them clinically manifest mucocutaneously. One of the possible mucocutaneous manifestation besides cutaneous vasculitis, prophyria cutanea tarda and prurigo is considered to be LP, thus LP could be overt clinical sign for an occult chronic hepatitis³.

The association between HCV infection and LP comes from epidemiological studies that have shown that the prevalence of antibodies against HCV antigens is higher in patients with LP than in general population²³.

In our study we found HCV antibodies in 27 of 70 cases of LP (38.6%) with a highly significant ($p = 0.000$), compared to the control group (10%). Our results support possible relationship between LP and HCV infection. These observations were in accordance Tonsi and Samdani who found that HCV antibodies were higher in patients suffering from LP (26.3%) than those in the control group (4.6%)¹⁰. On the contrary Stojanović had found that there was no statistically significant difference between the study and the control group regarding anti-HCV antibody prevalence¹¹.

In our study, total bilirubin was insignificant higher in the study group (LP) than in the control group ($p = 0.094$), also serum AST ($p = 0.298$). These observations were in accordance with the findings of the study conducted by Ghodsi who found that AST levels and bilirubin concentrations were higher than the normal range in patients with LP but without significant difference in the liver function tests between HCV infected and non infected groups²⁴.

The estimated mean age of LP in the present study was (46.1 years old) this quite dental to the belief of LP being a primarily disease of middle age with mean age of onset in the fourth to fifth decade²³.

In the present study, males and females were nearly affected with LP. This observation was in accordance with study conducted by Mignogna et al, who found that LP most commonly affected middle aged adults of both sex with a slight predominance in women²³.

5. Conclusion:

Our results support a possible relationship between LP and HCV. Thus, from this study, it seems that the HCV antibody test is necessarily required for LP patients with no signs of liver disease, because it has been established that early successful treatment of HCV infection prior to overt end-stage disease leads to dramatic improvement of inflammatory liver damage and fibrosis.

Corresponding author

Hasnaa A. Abo-Elwafa
Clinical Pathology Department Faculty of Medicine,
Sohag University, Egypt

* aboelwafahasnaa@yahoo.com

6. References:

- 1- Wolf DC (2010): Viral hepatitis. Medscape.
- 2- Galossi A, Guarisco R, Bellis L and Puoti C (2007): Extrahepatic manifestations of chronic HCV infection. *J Gastrointest Liver Dis*, 16(1):65-73.
- 3- Zignego AL, Ferri C, Pileri SA, Caini P and Bianchi FB (2007): For the Italian Association of the Study of Liver (A.I.S.F) Commission on Extrahepatic Manifestations of HCV Infection. Extrahepatic Manifestations of Hepatitis C Virus Infection: A general overview and guidelines for a clinical approach. *Dig Liver Dis*; 39:2-17.
- 4- Lehman EM and Wilson ML (2009): Epidemic hepatitis C virus infection in Egypt: estimates of past incidence and future morbidity and mortality. *J Viral Hepat*, 16(9):650-8.
- 5- Thomas DL, Ray SC and Lemon SM (2006): Hepatitis C. In: Mandell GL, Bennett JE, Dolin R, eds. *Mandell, Douglas, and Bennett's principles and practice of infectious diseases*. 6th ed. Elsevier Churchill Living Stone, 1950-1981
- 6- Matičič M (2007): Lichen planus in hepatitis C virus infection: an early marker that may save lives. *Acta Dermatoven APA*, 16:1.
- 7- Friedrich-Rust M, Ong MF and Martens S (2008): Performance of transient elastography for the staging of liver fibrosis: a meta-analysis. *Gastroenterology*, 134(4): 960-74.
- 8- Nelson D R, Davis GL and Jacobson I (2009): Hepatitis C virus: a critical appraisal of approaches to therapy. *Clin Gastroenterol Hepatol*, 7(4): 397-414; quiz 366.
- 9- Daoud MS and Pittelkow MR (2003): Lichen planus, in: Irwin M. Freedberg, Arthur Z, Eisen, Klous Wolff, (eds): *Fitzpatrick's Dermatology in general medicine*. 6th edition, Mc Graw-Hill, vol I, ch 49, pp 463-481

- 10- Tonsi A and Samdani AJ (2005): Association of lichen planus with hepatitis C virus infection. *Ann Saudi Med* 25(3):243-246.
- 11- Stojanović L, Lunder T, Poljak M, Matš T, Malakar B and Matičič M (2008): Lack of evidence for hepatitis C virus infection in association with lichen planus. *International Journal of Dermatology*, 47:1250-1256.
- 12- Van Der Meij EH and Van Der Waal I (2000): Hepatitis C virus infection and oral lichen planus: A report from the Netherland. *J Oral Pathol Med* 29:255.
- 13- Poynard T, McHutchinson J and Davies GL (2000): Impact of interferon alfa-2b and ribavirin on progression of liver fibrosis in patients with chronic hepatitis C. *Hepatology*, 32:1131-7.
- 14- Carrozzo M and Gandolfo S (2003): Oral diseases possibly associated with hepatitis C virus. *Crit Rev Oral Biol Med*, 14: 115-27.
- 15- Gene H Kim MD and Radha Mikkilineni MD (2007): Lichen planus actinicus. *Dermatology Online Journal*, 13 (1): 13.
- 16- Lodi G, Scully C and Carrozzo M (2005): Current controversies in oral lichen planus: Report of an international consensus meeting. Part 1. Viral infections and etiopathogenesis. *Oral Surg Oral Med Oral Pathol Oral Radiol Endod*, 100:40-51.
- 17- Carrozzo M, Brancatella F and Danatto E (2005): Hepatitis C virus-associated oral lichen planus: Is the geographical heterogeneity related to HLA-DR6? *J Oral Pathol Med*, 34:204-8.
- 18- Meyer S, Burgdorff T and Szeimies RM (2005): Management of erosive lichen planus with topical tacrolimus and recurrence secondary to metoprolol. *J Eur Acad Dermatol Venereol*, 19:236-239.
- 19- Choo QL, Kuo G and Weiner AJ (1989): Isolation of a cDNA clone derived from a blood-born non-A, non-B viral hepatitis genome. *Science*, 244:359-62.
- 20- Erkek E, Bozdogan Ö and Olut AI (2001): Hepatitis C virus infection prevalence in lichen planus: examination of lesional and normal skin of hepatitis C virus-infected patients with lichen planus for the presence of hepatitis C virus RNA. *Clin Exp Dermatol*, 26:540-544.
- 21- Prabhu S, Pavithran K and Sobhanadevi G (2002): Lichen planus and hepatitis C virus (HCV)- Is there an association? A serological study of 65 cases. *Indian Journal of Dermatology, Venereology and Leprosy*, 68(5):273-274.
- 22- Arrieta JJ, Rodriguez-Inigo E, Casqueiro, Bartolome J, Manzarbeitia F and Herrero M (2000): Detection of hepatitis C virus replication by in situ hybridization in epithelial cells of anti-hepatitis C virus-positive patients with and without oral lichen planus. *Hepatology*, 32:97-103.
- 23- Mignogna MD, Lo Muzio L, Lo Russo L, Fedele S, Ruoppo E and Bucci E (2000): Oral lichen planus: different clinical features in HCV-positive and HCV-negative patients. *Int J Dermatol* 39:134-139.
- 24- Ghodsi SZ, Daneshpazhoo M, Shahi M and Nikfarjam A (2004): Lichen planus and Hepatitis C: a case-control study. *BMC Dermatol*, 4:6.

12/22/2010